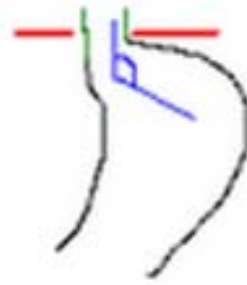
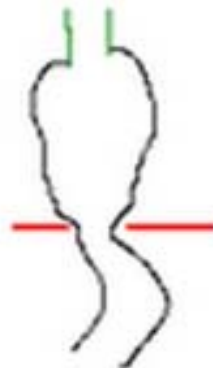


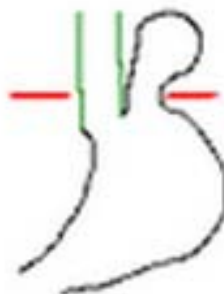
Normal anatomy



Early stage of hiatal hernia



Sliding hiatal hernia



Paraesophageal hernia

- esophagus
- diaphragm
- stomach
- angle of fundus (upper stomach)